

Osteólise Umeral: Complicação Rara da Osteomielite

Massive Humeral Osteolysis: A Rare Complication of Osteomyelitis

Ana Luísa Lourenço⁽¹⁾ | Lúcia Nascimento⁽¹⁾ | Pedro Alves⁽¹⁾ | Maria José Costa⁽²⁾

Resumo

Introdução: A osteomielite pode causar complicações muito graves, nomeadamente osteólise com reabsorção de segmentos ósseos. Atualmente esta complicação é bastante rara devido ao diagnóstico precoce e à disponibilidade de terapêutica antibiótica e cirúrgica.

Caso Clínico: Descrevemos o caso de uma criança de seis anos referenciada à nossa instituição por uma extensa osteólise umeral causada por uma pan-osteomielite do braço direito, sem intervenção cirúrgica prévia. O exame objetivo revelou deformidade do braço pela ausência de suporte ósseo, contudo, discretos movimentos de extensão/flexão do cotovelo e elevação do ombro estavam conservados.

Discussão: Este trabalho descreve um caso muito raro de extensa osteólise umeral causada por osteomielite. É um caso interessante não só pela sua raridade e exuberante forma de apresentação imagiológica e clínica, mas também pelo facto de a criança preservar alguns movimentos do braço, com recurso a mecanismos de compensação/recrutamento.

Palavras-chave: Osteólise/diagnóstico por imagem; Osteomielite/complicações; Úmero.

Abstract

Introduction: Osteomyelitis may lead to severe complications, such as bone necrosis, which can result in segmental bone defects. Nowadays, this is a very rare complication due to the proper antibiotic therapy and surgical management.

Case Report: We describe the case of a six-year-old child referred to our institution with a massive humeral osteolysis due to a complication from a right arm pan-osteomyelitis, without previous surgical intervention. Physical examination revealed a deformable arm due to bone support absence. However, some movements of elbow flexion/extension and shoulder elevation were still preserved.

Discussion: This paper describes a very rare case of an extensive bone segmental osteolysis due to osteomyelitis, which is interesting not only for its rarity and peculiar imaging and clinical presentation, but also for the fact that the child preserves some arm movements, using compensation/recruitment mechanisms.

Keywords: Humerus; Osteolysis/diagnostic imaging; Osteomyelitis/complications.

Introduction

Acute osteomyelitis represents an inflammatory and infectious involvement of a bone segment and is primarily caused by bacterial infection. Pathogenesis includes three different mechanisms: hematogenous spread, extension by contiguity or penetration of the infectious agent. The first mechanism is the most commonly described in paediatric patients.^{1,2} *Staphylococcus aureus* is the most frequent pathogen, however, in children less than two months of age, *Streptococcus agalactiae* and other Gram-negative organisms are potential pathogens. In children between two and five years-old, *Streptococcus pyogenes* and *Streptococcus pneumoniae* should also be considered.^{1,3} *Salmonella* spp. is a frequent pathogen in developing countries, especially in patients with sickle cell disease.¹

(1) Radiology department. Hospital Dona Estefânia, Centro Hospitalar e Universitário de Lisboa Central, Lisboa, Portugal

(2) Physical Medicine and Rehabilitation department. Hospital Dona Estefânia, Centro Hospitalar e Universitário de Lisboa Central, Lisboa, Portugal

© Autor (es) (ou seu (s) empregador (es)) e Revista SPMFR 2020. Reutilização permitida de acordo com CC BY-NC. Nenhuma reutilização comercial.

© Author(s) (or their employer(s)) and SPMFR Journal 2020. Re-use permitted under CC BY-NC. No commercial re-use.

Autor correspondente: Ana Luísa Lourenço. ana.lmlourenco@gmail.com. Serviço de Radiologia, Centro Hospitalar e Universitário de Lisboa Central, Alameda Santo António dos Capuchos, 1169-050 Lisboa

Data de submissão: maio 2020

Data de aceitação: outubro 2020

Data de publicação: dezembro 2020

Infection is initially established in the tubular bones' metaphyseal region. Appendicular skeleton is the most common affected; the lower extremity, especially the femur, is involved more often than the upper extremity, where the humerus is more likely to be involved.⁴

Considering clinical presentation, acute hematogenous osteomyelitis has two distinct presentations: an acutely ill, febrile child who has systemic inflammatory symptoms and typical signs of septicaemia, with additional focal findings of skeletal infection; and a child who may be afebrile or have low-grade fever and demonstrates a gradual progression of symptoms and signs of bone infection, manifested with pain and tenderness at the site of infection, that may deteriorate with movement and weightbearing.^{1,4,5}

Most children with acute hematogenous osteomyelitis have peripheral leucocytosis at presentation. The erythrocyte sedimentation rate is often normal or slightly elevated during the first days and may not rise substantially until approximately seven days after the onset of the infection. Serum C-reactive protein concentrations tend to become elevated sooner than erythrocyte sedimentation rate.

Concerning imaging evaluation, plain radiographs usually demonstrate abnormalities ten to fourteen days after the onset of the disease. The earliest abnormalities are seen in the adjacent soft tissues and muscle outlines, with swelling and loss or blurring of fat planes. An effusion may be noticed in the adjacent joint. The ultrasound has a little role in the direct assessment of the bone structure. It is useful for soft tissues evaluation, being able to identify abscesses, cellulitis, subperiosteal collections and joint effusions. Magnetic resonance (MR) is the most sensitive and specific imaging modality. It is able to identify bone marrow oedema in early phases (one or two days after the onset of the infection) and also to evaluate soft-tissue/joint complications adjacent to the infected bone.⁴

Antibiotic therapy is the gold standard treatment in the acute osteomyelitis, being initially empirical considering the child age and epidemiology context.¹ In acute uncomplicated osteomyelitis, surgery may not be necessary. It should be considered in patients who do not respond to antibiotic treatment or when an underlying complication is suspected.^{6,7}

Chronic osteomyelitis is defined by the persistent residual foci of infection (avascular bone and soft tissue debris), which leads to recurrent episodes of clinical infection. It can result from untreated acute hematogenous osteomyelitis, after traumatic injuries or surgical complication. Chronic osteomyelitis in children is rare in industrialised nations but continues to be a significant cause of morbidity globally. No

accurate data on the incidence and prevalence is described on literature.⁸

Children who develop acute osteomyelitis can develop chronic disease, especially if they live in areas where health services are inadequate. Predisposing factors include poor hygiene, anaemia, malnutrition and a coexisting infectious disease (parasites, mycobacteria, acquired autoimmune deficiency syndrome) or any other issues that decrease immune status. Function in the affected limb is often severely impaired by pain, joint stiffness, angular deformity, limb length discrepancy or lack of skeletal structural integrity. The child often lives with a chronic discharging sinus.⁸

Long bones are the most commonly affected (femur and tibia account for approximately half of the cases). There is a risk of coexisting septic arthritis, especially in children with less than two years of age, as a result of the unique aspects of the infant's vasculature. The metaphyseal and epiphyseal vessels communicate until approximately 12 to 18 months of age, after which the physis serves as a mechanical barrier to the spread of infection. The clinical findings include fever, malaise, bone pain, tenderness, soft tissue swelling and a sinus with persistent discharge can often be noticed.⁸ Inhomogeneous osteosclerosis and/or sequestrum formation is characteristic for chronic osteomyelitis on plain radiography. A sequestrum represents a segment of necrotic bone that is separated from the living bone by granulation tissue and bone resorption. It is typically denser than the living bone. In some cases, a layer of new periosteal bone or involucrum is formed around the necrotic bone. On MR, the sequestrum is hypointense on all pulse sequences. The cloaca is an opening in the involucrum, which allows drainage of purulent and necrotic material out of the dead bone. If the tract extends to the skin surface, the portion extending beyond the involucrum to the skin surface is called a sinus tract. Gadolinium contrast administration may reveal more accurately the cloaca and the sinus tract. Computed tomography (CT) may provide information regarding the presence of sequestrum, cloaca, cortical destruction and the thickness of the involucrum. CT and US can be performed for imaging-guided needle biopsy and aspiration material for microbiology.^{9,10}

The basic aims of treatment are the eradication of infection, maintenance or restoration of the structural integrity of the skeleton, prevention or correction of deformity and return to adequate function. It is generally accepted that the treatment of chronic osteomyelitis in childhood consists of adequate surgical debridement. The exclusive antibiotic treatment will not be sufficient especially in cases of formation of sequestrum. The timing of surgical intervention is controversial. Some authors recommend early

sequestrectomy to eradicate the infection and provide a better environment for the periosteum to respond. However, others authors recommend waiting until a sufficient involucrum has formed before performing a sequestrectomy to minimize the risk of complications such as fracture, non-union, deformity and segmental bone loss.^{8,11,12} When the pattern of disease is simple, this may be achieved relatively easily by sequestrectomy and curettage. In more complex patterns of disease where there is a pathological fracture, growth disruption, bone loss, joint involvement or severe soft-tissue damage. Achieving good results can be difficult, expensive and time-consuming.⁸ The recurrence rate after the surgical intervention is reported to be 10-30%.¹³ In chronic osteomyelitis, eradication of the infection is difficult and complications associated with both the infection and its treatment are very common.

Case Report

A six-year-old child from Cape Verde with a sequela from an osteomyelitis was referred to a medical paediatrics appointment at our institution. She has a past medical history of a severe pan-osteomyelitis of the right arm when she was three-year-old, in need for long hospitalization in her homeland. We did not have access to her past medical

reports, antibiotic therapy description, previous imaging or laboratory exams, which impairs the proper characterization of the infection disease evolution. The parents denied past surgical interventions. On physical examination performed at our institution the child was afebrile. The cutaneous surface of the right arm was smooth and homogeneous, with no signs of sinus tract or surgical scars. Physical examination also revealed a deformable and shortened right arm, with diffuse muscular atrophy involving the shoulder and the arm compartments (Fig. 1).

Upper right limb articular amplitudes were preserved. Distal active movements (wrist and hand) were maintained in the anatomic position. Shoulder main movements were essentially scapulothoracic. Upper limb active joint mobility was limited and totally dependent on support muscles (axial body, contralateral upper limb and / or lower limbs), other joints coupled actions, and gravity. Fig. 2 shows a simultaneous bilateral shoulder abduction attempt, which triggered an elevation and protraction of the scapula and clavicle, and a glenohumeral joint extension (scapula-clavicle-humeral rhythm).

The inefficacy of the triceps brachii muscle contraction due to the absence of humeral bone support, allows elbow flexion by a gravitational process. Support muscles (cervical iliocostalis muscles) are simultaneously activated by the

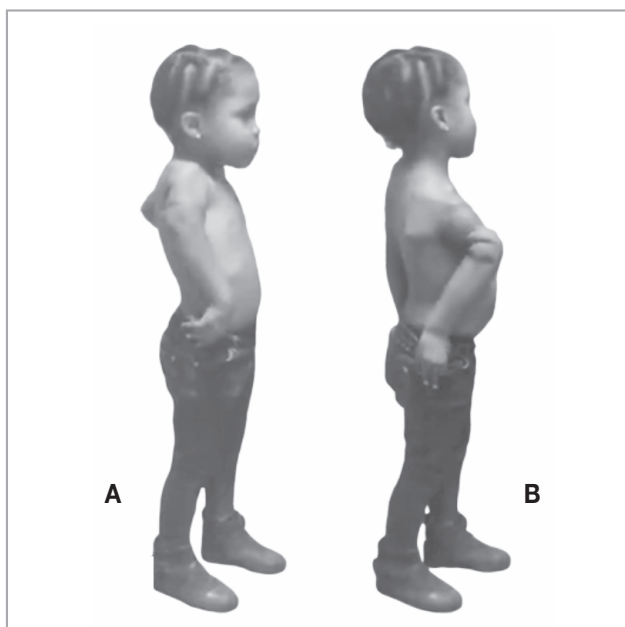


Figure 1 - A and B show deformity and shortening of the right arm, while the child tries to reach the right back pocket.

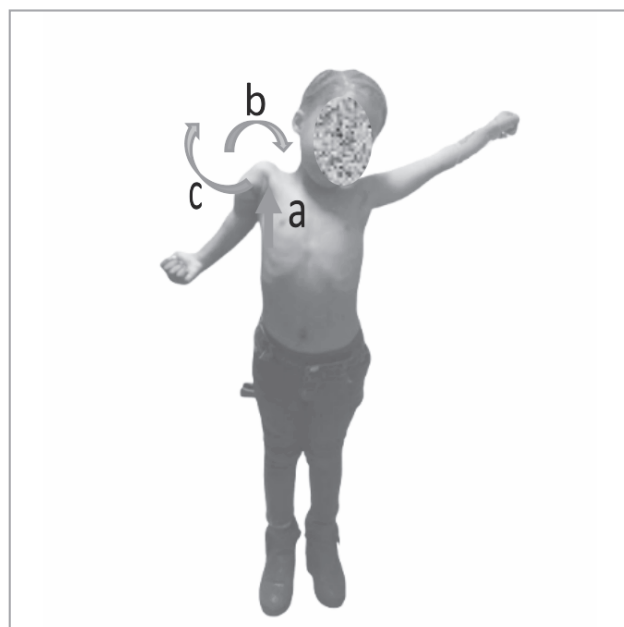


Figure 2 - Bilateral shoulder simultaneous abduction: (a) elevation and (b) protraction of the scapula and clavicle and (c) glenohumeral joint extension (scapula-clavicle-humeral rhythm).

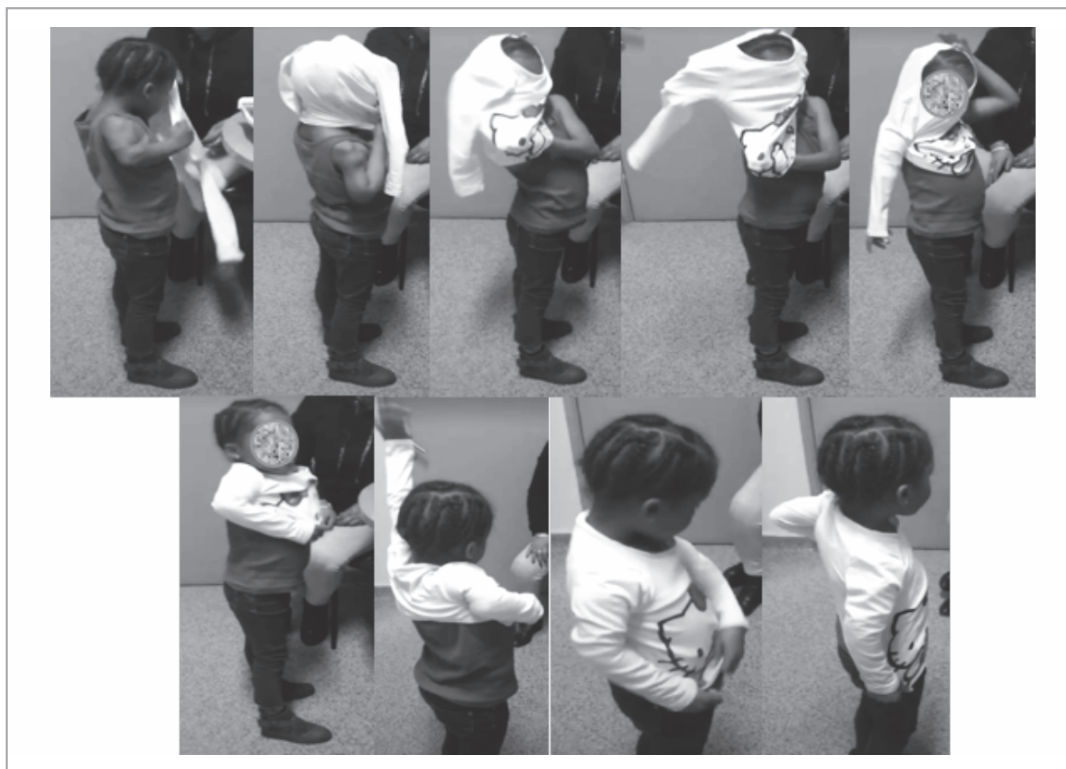

Figure 3 - ADL example: dress a shirt using compensation/recruitment mechanisms: muscular, articular and gravitational.

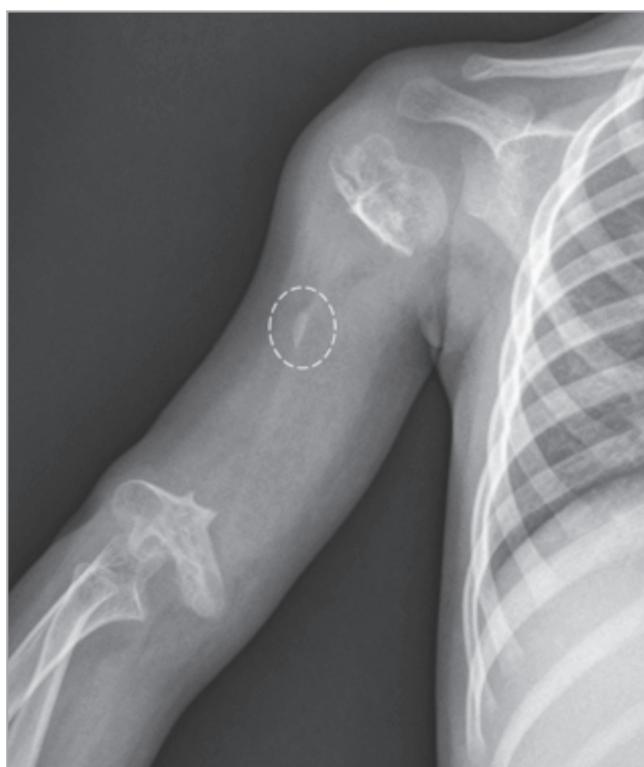

Figure 4 - Right arm plain film demonstrates a massive humeral diaphysis and metadiaphyses bone loss. Proximal and distal epiphysis are still preserved, although deformed. A very small diaphysis' fragment can be depicted (dashed circle).

extension and left leaning of the torso. Automatic recruitment mechanisms are initiated in order to compensate the right arm bone and muscular loss.¹⁴ The movement of touching the mouth with the right hand was a good example of these mechanisms: the child initiated a torso mobilization and a right upper limb pendulum movement (gravity), with shoulder flexion. Then, the child forced elbow flexion by grabbing the right forearm with the contralateral left hand and, finally, touched the mouth with her right hand. Speed is a very important element of this automatic recruitment mechanism. Using these mechanisms, the child is able to keep several activities of daily living (ADL), such as dress and undress (trousers, shirts, etc.), without third-party help (Fig. 3).

No abnormalities were perceived in blood workup. A plain radiograph and a MR were performed for a more accurate characterization of the clinical case. The plain radiograph demonstrated absence of the humeral diaphysis and both of the metadiaphyses; the proximal and distal epiphyses were preserved, although they were deformed (Fig. 4).

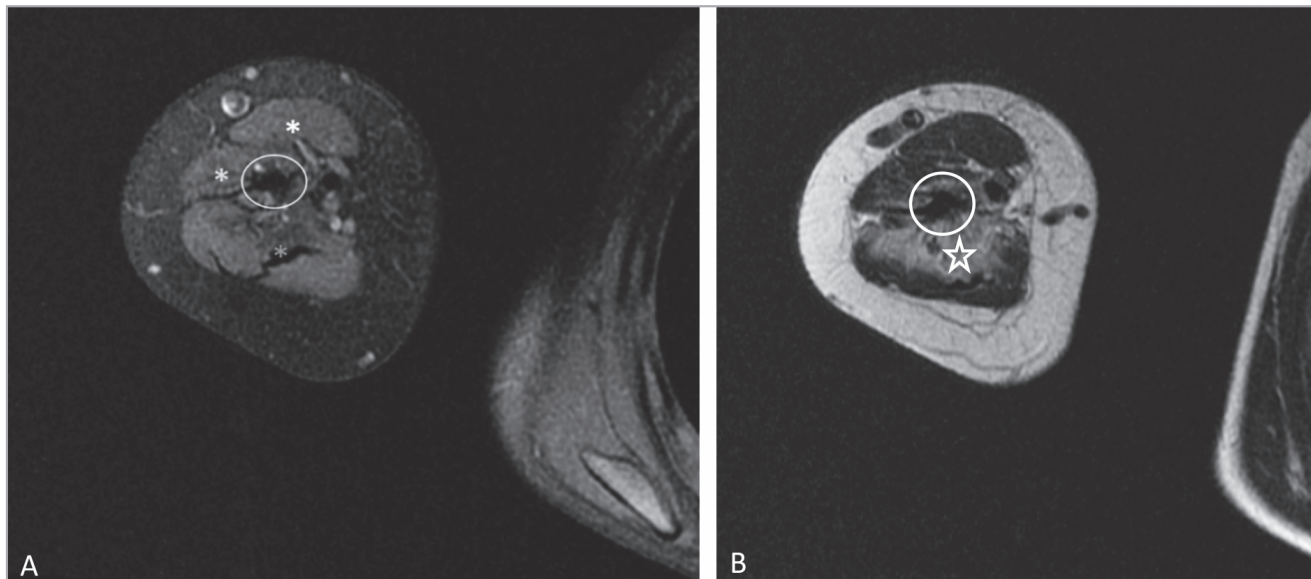


Figure 5 - (A) Axial fat-suppressed proton-density weighted **(A)** and axial T2 weighted **(B)** MR images demonstrate a central low signal instead of the normal bone signal (white circles), compatible with fibrous tissue. Although atrophied, arm muscle compartments are preserved. We can appreciate the biceps brachii muscle (white asterisk), the brachialis muscle (yellow asterisk) and the triceps brachii muscle, posteriorly (red asterisk). **(B)** Axial T2 weighted image shows triceps brachii muscle atrophy and fatty degeneration, especially involving the medial head (star).

MR demonstrated low signal intensity on both T1 and T2-weighted images, replacing the bone signal on the diaphysis and on both the metadiaphyses, compatible with fibrous tissue. No signs of active inflammation/infection were detected. Arm muscle compartments were preserved, although atrophied and with severe fatty degeneration, especially in the posterior compartment (Fig. 5).

Taking into account these clinical and radiological findings, the child was evaluated by a multidisciplinary group, involving specialists from medical pediatrics, physical medicine and rehabilitation and orthopedics. The purpose was to understand the protentional benefits of a surgical and/or conservative therapeutic approach.

Discussion

As above-mentioned, the metaphysis is the primary focus of the acute hematogenous osteomyelitis in children. If untreated, the intramedullary pressure increases and the exudate spreads through the thin metaphyseal cortex resulting in a subperiosteal abscess and osteonecrosis, caused by disruption of intraosseous and periosteal blood supply during the acute stage of the disease. Avascular segments of bone are known as sequestrum, which can involve the entire long bone shaft. The host response tries to wall off or reabsorb these fragments (involucrum) in an attempt to re-establish stability. If this process fails, then

focal or segmental bone loss is often inevitable.⁸ Pathological fractures are also increased in osteomyelitis, mostly in the early stages of the disease, before the involucrum creation, which may be complicated with non-union and the possibility of subsequent segmental bone loss.^{5,12,15}

Our case report describes a massive bone loss of the humeral diaphysis in a child with a past medical history of an acute osteomyelitis. The fact that we did not have access to the medical reports, including the description of previous antibiotic therapeutic, impairs the clinical case understanding. The long hospitalization period at her homeland and the massive bone loss noticed in the radiological studies, favours the occurrence of a chronic osteomyelitis which resulted from a refractory acute osteomyelitis. Bone segmental defects are more commonly described in the literature after extensive surgical debridement of the bone. However, no cutaneous scars were detected in the physical examination. Therefore, we believe that this case report represents a case of spontaneous bone osteolysis after osteomyelitis, in which the bone infection evolved to a massive segmental bone necrosis and, consequently, to bone reabsorption. Since the child was three years-old when the infection started, the physes probably behaved as a barrier to progression to a septic arthritis, perhaps in association with antibiotic regimen, which can explain why the epiphyses are still preserved.

Despite the loss of the diaphysis and both the metadiaphysis, the child preserves some muscle component and developed compensation/recruitment mechanisms (based on support muscles, coupled actions and gravity), which allow her to keep autonomy in her ADL. Consequently, it was not considered necessary to implement conservative rehabilitation measures. In terms of surgical treatment, this case constitutes a huge challenge because of the extent of bone loss, since segmental defects greater than 2 cm in length may be difficult to manage using conventional grafting.¹² In this particular case report, two main surgical techniques could be performed, a circular external fixation, known as Ilizarov technique, and the Masquelet technique. The latter consists of a two-step procedure. In the first one, a bone cement spacer is introduced in the bone defect followed by a reconstruction of the soft tissue. The spacer induces a foreign body reaction with the formation of a well vascularized membrane. In the second step, performed after six to eight weeks, the spacer is removed and the defect is filled with bone graft.¹⁶

Once more, since the child was very well adapted to her ADL, the multidisciplinary team decided not to perform any orthopaedic surgical procedure, because the result could restrict the child's adaptative movements afore mentioned. On the other hand, some of these adaptative muscular maneuvers involve bizarre movements, for example deformity and/or shortening of the arm (Fig.1). In the future, these repeated movements can lead to harmful effects, such as, muscle damaging. Taking into account these aspects and in order to provide some support to the right upper limb, it is being considered the creation of an orthosis device, made by multiperforated thermoformable material. It is still very early to understand the possible beneficial impact of this therapeutic measure.

Unquestionably, the diagnosis of paediatric bone infections can constitute a huge challenge, either in diagnosis and also in treatment. Knowledge is essential for its detection and for outline an effective therapeutic intervention, in order to prevent potentially devastating complications.

Conflitos de Interesse: Os autores declaram a inexistência de conflitos de interesse na realização do presente trabalho. **Fontes de Financiamento:** Não existiram fontes externas de financiamento para a realização deste artigo. **Confidencialidade dos Dados:** Os autores declaram ter seguido os protocolos da sua instituição acerca da publicação dos dados de doentes. **Consentimento:** Consentimento do doente para publicação obtido. **Proveniência e Revisão por Pares:** Não comissionado; revisão externa por pares.

Conflicts of Interest: The authors have no conflicts of interest to declare. **Financing Support:** This work has not received any contribution, grant or scholarship. **Confidentiality of Data:** The authors declare that they have followed the protocols of their work center on the publication of data from patients. **Patient Consent:** Consent for publication was obtained. **Provenance and Peer Review:** Not commissioned; externally peer reviewed.

Referências / References

- Castellazzi L, Mantero M, Esposito S. Update on the Management of Pediatric Acute Osteomyelitis and Septic Arthritis. *Int J Mol Sci.* 2016; 17: 855-63. doi:10.3390/ijms17060855
- Arnold JC, Bradley JS. Osteoarticular infections in children. *Infect Dis Clin N Am.* 2015; 29: 557-74. doi: 10.1016/j.idc.2015.05.012
- Principi N, Esposito S. Infectious discitis and spondylodiscitis in 4. Conrad DA. Acute hematogenous osteomyelitis. *Ped Rev.* 2010; 31:464-71. doi: 10.1542/pir.31-11-464
- Shukrimi A, Ariff MS, Zamzuri Z, Mai Ashikin NT. Chronic Tibial Osteomyelitis in Children. A Case Review at Hospital Tengku Ampuan Afzan, Kuantan. *Med J Malaysia.* 2015; 70: 48-51.
- Agarwal A, Aggarwal AN. Bone and joint infections in children: Acute hematogenous osteomyelitis. *Indian J Pediatr.* 2015; 83:1-8. doi: 10.1007/s12098-015-1806-3
- Pääkkönen M, Peltola H. Management of a child with suspected acute septic arthritis. *Arch Dis Child.* 2012; 97: 287-92. doi: 10.1136/archdischild-2011-300462
- Jones H, Beckles V, Akinola B, Stevenson A, Harrison W. Chronic haematogenous osteomyelitis in children. An unsolved problem. *J Bone Joint Surg.* 2011;93-B:1005-10. doi:10.1302/0301-620X.93B8.25951
- Desimpel J, Posadzy M, Vanhoenacker FM. The many faces of osteomyelitis: a pictorial review. *J Belg Soc Radiol.* 2017;101:24. doi: 10.5334/jbr-btr.1300.
- Pineda C, Espinosa R, Pena A. Radiographic imaging in osteomyelitis: the role of plain radiography, computed tomography, ultrasonography, magnetic resonance imaging, and scintigraphy. *Semin Plast Surg.* 2009;23:80-9. doi: 10.1055/s-0029-1214160.
- Pincher B, Fenton C, Jeyapalan R, Barlow G, Sharma HK. A systematic review of the single-stage treatment of chronic osteomyelitis. *J Orthop Surg Res.* 2019;14:393. doi: 10.1186/s13018-019-1388-2.
- Spiegel DA, Penny JN. Chronic Osteomyelitis in Children. *Tech Orthop.* 2005; 20:142-152. doi: 10.1097/01.bto.0000162988.21990.f6
- Wirbel R, Hermans K. Surgical treatment of chronic osteomyelitis in children admitted from developing countries. *Afr J Paediatr Surg.* 2014;11:297-303. doi: 10.4103/0189-6725.143133.
- Muscolino JE, editor. *Kinesiology: the skeletal system and muscle function.* 3rd ed. Amsterdam: Elsevier; 2017.
- Weissman SL, Salama R. Spontaneous osteolysis following acute osteomyelitis. *JAMA.* 1962; 182: 1122-3. doi:10.1001/jama.1962.03050500054015b
- Lasanianos N, Kanakaris N, Giannoudis P. Current management of long bone large segmental defects. *Orthop Trauma J.* 2009; 24: 149-63. doi:10.1016/j.morth.2009.10.003